

---

# Cutaneous scarring: Pathophysiology, molecular mechanisms, and scar reduction therapeutics

## Part II. Strategies to reduce scar formation after dermatologic procedures

Christos Tziotzios, MA, MB, BChir (Cantab), MRCP (UK),<sup>a</sup> Christos Profyris, MA, BM, BCh (Oxon), MRCS (Eng),<sup>b</sup> and Jane Sterling, MA, MB, BChir, PhD (Cantab), FRCPC<sup>c</sup>  
*Cambridge and London, United Kingdom*

### CME INSTRUCTIONS

The following is a journal-based CME activity presented by the American Academy of Dermatology and is made up of four phases:

1. Reading of the CME Information (delineated below)
2. Reading of the Source Article
3. Achievement of a 70% or higher on the online Case-based Post Test
4. Completion of the Journal CME Evaluation

#### CME INFORMATION AND DISCLOSURES

##### Statement of Need:

The American Academy of Dermatology bases its CME activities on the Academy's core curriculum, identified professional practice gaps, the educational needs which underlie these gaps, and emerging clinical research findings. Learners should reflect upon clinical and scientific information presented in the article and determine the need for further study.

##### Target Audience:

Dermatologists and others involved in the delivery of dermatologic care.

##### Accreditation

The American Academy of Dermatology is accredited by the Accreditation Council for Continuing Medical Education to provide continuing medical education for physicians.

##### AMA PRA Credit Designation

The American Academy of Dermatology designates this journal-based CME activity for a maximum of 1 *AMA PRA Category 1 Credits*<sup>SM</sup>. Physicians should claim only the credit commensurate with the extent of their participation in the activity.

##### AAD Recognized Credit

This journal-based CME activity is recognized by the American Academy of Dermatology for 1 AAD Recognized CME Credit and may be used toward the American Academy of Dermatology's Continuing Medical Education Award.

##### Disclaimer:

The American Academy of Dermatology is not responsible for statements made by the author(s). Statements or opinions expressed in this activity reflect the views of the author(s) and do not reflect the official policy of the American Academy of Dermatology. The information provided in this CME activity is for continuing education purposes only and is not meant to substitute for the independent medical judgment of a healthcare provider relative to the diagnostic, management and treatment options of a specific patient's medical condition.

##### Disclosures

###### Editors

The editors involved with this CME activity and all content validation/peer reviewers of this journal-based CME activity have reported no relevant financial relationships with commercial interest(s).

###### Authors

The authors of this journal-based CME activity have reported no relevant financial relationships with commercial interest(s).

###### Planners

The planners involved with this journal-based CME activity have reported no relevant financial relationships with commercial interest(s). The editorial and education staff involved with this journal-based CME activity have reported no relevant financial relationships with commercial interest(s).

###### Resolution of Conflicts of Interest

In accordance with the ACCME Standards for Commercial Support of CME, the American Academy of Dermatology has implemented mechanisms, prior to the planning and implementation of this Journal-based CME activity, to identify and mitigate conflicts of interest for all individuals in a position to control the content of this Journal-based CME activity.

###### Learning Objectives

After completing this learning activity, participants should be able to describe the variety of approaches commonly used by the practicing dermatologist for scar reduction; delineate the scientific evidence for currently available antiscarring agents; discuss novel and promising antiscarring agents; correlate the mechanism of action of these innovative agents and some of the conventional modalities with the molecular pathophysiology of cutaneous scarring; and discuss the value of translational research and describe the rationale for further work in this area.

**Date of release:** January 2012

**Expiration date:** January 2015

© 2012 by the American Academy of Dermatology, Inc.  
doi:10.1016/j.jaad.2011.08.035

The evidence base underpinning most traditional scar reduction approaches is limited, but some of the novel strategies are promising and accumulating. We review a number of commonly adopted strategies for scar reduction. The outlined novel agents are paradigmatic of the value of translational medical research and are likely to change the scenery in the much neglected but recently revived field of scar reduction therapeutics. (*J Am Acad Dermatol* 2012;66:13-24.)

**Key words:** antiscarring agents; cutaneous scar reduction strategies.

**ANTISCARRING STRATEGIES**

A cutaneous scar results from overgrowth of fibrous tissue after damage to the skin after injury or surgery and represents an exuberant healing response.<sup>1</sup> The type of scar depends on how exuberant the healing response is, with hypertrophic scars not extending beyond the wound borders and keloids extending. The former are clinically more favorable than the latter because they are more amenable to treatment and often even regress spontaneously.<sup>2</sup> Both types of cutaneous scarring are underpinned by similar pathobiologic processes, and it is not surprising that they respond to the same physical or pharmacologic interventions. They are managed similarly and we therefore refer to the two terms interchangeably in this article.

Hypertrophic and keloid scars can be associated with physical and psychological symptoms, yet no major advances have been achieved so far in scar reduction therapeutics. This is probably because of the limited commercial interest and subsequently insufficient research investment in the field. Little research investment entails little product return and little evidence basis for any conventional treatment modality.

In Part II of this review, we aim to recap and evaluate management steps that can be taken to reduce the risk of hypertrophic or keloid scarring and to treat such scars if they develop (please see [Table I](#) for an overview), and also to look to the future

for therapies that may give a better result profile for skin surgery. The value of translational research will become apparent, and we recommend consulting part I of this review for a better appreciation of the molecular basis of scar therapeutics.

**CAPSULE SUMMARY**

- “Will there be a scar?” From minor operative procedures to trauma-related surgery, this question is often at the center of patient-related concerns.
- In order to address the aforementioned common clinical question, this review aims at critically reviewing conventional and innovative strategies that may be adopted to minimize scarring following dermatologic procedures.
- Identifying high risk is paramount to hypertrophic scar prophylaxis, as is clean surgery and good wound care.
- Nonsurgical scar reduction strategies include numerous over-the-counter products, such as onion extracts and Vitamin E -based remedies, not supported by a sufficient evidence base.
- Intralesional corticosteroids, 5-fluorouracil, bleomycin, and lasers are commonly used in clinical practice, while radiation and surgical revision are only seldom-used modalities.
- Human recombinant interleukin-10 and, to a lesser extent, mammose-6-phosphate, are innovative and promising products of translational research that are currently under development for cutaneous scar reduction.
- More extensive and better trials are essential for numerous other agents that have shown promise but have been tested only sporadically.

**PRACTICAL  
PROPHYLACTIC  
CONSIDERATIONS****Key points**

- **Identifying high risk is paramount to preventing hypertrophic scarring after dermatologic procedures**
- **Certain high-pressure body sites are more likely to show exaggerated scarring, and patients of Afro-Caribbean descent and those with personal or family history of scarring are at increased risk of engaging in such a response**
- **Minimizing skin tension and the inflammatory response after surgery by using the appropriate materials and ascertaining clean surgery and good wound care are simple practical prophylactic measures**

An individual at increased risk of developing a thickened scar may benefit from certain prophylactic measures to reduce this risk when skin surgery is contemplated. If surgery is urgent or if the procedure is of medical importance, such as skin cancer therapy, then a detailed approach to scar minimization measures may seem irrelevant.

From Addenbrooke's Hospital,<sup>a</sup> Cambridge University Hospitals NHS Foundation Trust, Cambridge; Department of Plastic and Burns,<sup>b</sup> Chelsea and Westminster Hospital, London; and the Department of Dermatology,<sup>c</sup> University of Cambridge, Cambridge University Hospitals NHS Foundation Trust, Cambridge, United Kingdom.

Reprint requests: Christos Tziotzios, MA, MB, BChir (Cantab), MRCP (UK), Addenbrooke's Hospital, Cambridge University Hospitals NHS Foundation Trust, Hills Road, Cambridge CB2 0QQ, Cambridge, United Kingdom. E-mail: [ct287@cantab.net](mailto:ct287@cantab.net).  
0190-9622/\$36.00

### Identify high risk

Injury to the dermis and dermoepidermal junction, either related to cutting injury or intense inflammation, triggers a repair process that will usually result in a scar. In only a minority of patients does the scar become thickened and hypertrophic.

The risk of a thickened scar after surgery is higher in certain body sites; the shoulder and scapular area, anterior chest, lower abdomen, earlobe, and any other cutaneous region overlying a bony prominence is more prone to an exaggerated scarring response.<sup>3</sup>

There is evidence to suggest that this natural tendency is explained by the increased mechanical tension that characterizes these body sites.<sup>4</sup> Patients of Afro-Caribbean descent and those with a personal or family history of thickened scars are more likely to produce this response. Young age (<30 years of age) is also a risk factor, especially for keloids,<sup>5,6</sup> and while little can be done to change the innate tendency of certain individuals or body sites, the dermatologic surgeon can take extra measures to reduce risk.

Of course, the dermatologic surgeon may well decide to adopt an approach whereby all patients are offered prophylactic treatment, especially when the latter is characterized by a safe adverse reaction profile or when cosmesis is of paramount importance to the patient.

### Reduce skin tension

Based on the aforementioned increased mechanical tension hypothesis, it makes sense to minimize mechanical forces after surgery. Surgical excision scars should be positioned, whenever possible, along rather than across relaxed skin tension lines. Appropriate strength, depth, and number of sutures should ensure that the risk of dehiscence is minimized. Using materials such as paper tape would be expected to facilitate this, and there is some evidence (albeit limited) in support of this idea.<sup>7,8</sup> Avoiding movements after surgery that cause excessive stretching and protecting the wound from friction would therefore be expected to be helpful.

### Minimize inflammation

Inflammation is also known to contribute to hypertrophic scarring,<sup>9</sup> and every attempt to minimize the inflammatory response should be made by ascertaining clean surgery and good wound care to prevent infection thereafter. Using inert suture materials would also be important in this context.

### Skin closure considerations

With regard to skin closure after excision, a 2010 Cochrane review reported sutures to be significantly

better than tissue adhesives for minimizing dehiscence.<sup>10</sup> The suture should be strong to avoid wound dehiscence, but it should also accommodate wound edema by allowing adequate stretching. Good eversion of the skin edges is important, as is uniform distribution of the suture tensile strength along the carefully approximated and evenly sutured skin counterparts.<sup>11</sup> Both vertical and horizontal mattress sutures afford excellent results—as do buried intradermal sutures<sup>12</sup>—and their early removal can minimize their classic “railway road” cutaneous scars.<sup>13</sup> Interestingly, randomized controlled trials comparing absorbable with nonabsorbable suture materials have not found any significant differences in the long-term cosmetic outcomes.<sup>14-16</sup> Nonabsorbable sutures have been reported to perform better in regions of high skin tension, such as the anterior chest wall.<sup>17</sup> A 2007 meta-analysis highlights the lack of large and methodologically sound randomized controlled trials comparing absorbable with nonabsorbable sutures.<sup>18</sup> In terms of suture material, monofilament sutures are preferred over braided sutures, because they have been reported to cause less inflammation<sup>19</sup>—but again, the conducted studies are neither large and sound nor adequate.

## NONSURGICAL SCAR REDUCTION STRATEGIES

### Key points

- **There are numerous antiscarring agents available over the counter, including silicone dressings, onion extract, and vitamin E–based remedies, none of which are supported by a sufficient evidence base**
- **There is some evidence base underpinning the use of intralesional corticosteroids, 5-fluorouracil, and bleomycin**

There is a multitude of commonly used over the counter scar treatment products that have little evidence-based efficacy.<sup>20,21</sup> Among these, silicone dressings, onion extract, and vitamin E–based remedies rank as the top selling products, despite lacking an evidence base.<sup>20-22</sup> Often, the advertised beneficial claims lure patients into seeking or purchasing such products, and clinicians should be aware of the disparity between advertised benefits and evidence in support of their efficacy.<sup>22</sup>

### Silicone dressings

Silicone-based products are widely available and have long been used for hypertrophic scar prophylaxis and treatment. They have been advocated by the 2001 International Advisory Panel for Hypertrophic Scarring and Keloid Management as a

viable treatment option<sup>23</sup> and have also been popular among plastic surgeons.<sup>24</sup> Their mode of action was thought to be by temperature, oxygen tension, and hydration regulation.<sup>6</sup> Despite intermittent reports of positive data in clinical studies and popularity in clinical practice, a recent Cochrane analysis has concluded that most evidence is of poor quality and highly susceptible to bias and therefore weak overall.<sup>21</sup>

The fact that silicone-based products are relatively inexpensive, readily available, noninvasive, and even remotely possibly beneficial to an extent may explain their lasting clinical popularity. They should be better explored by additional studies and used, in the interim, as adjuncts in hypertrophic scar management.

### Pressure dressings

Pressure garment therapy has been used for decades as a conservative means of preventing and managing hypertrophic scars.<sup>25</sup> Pressure-induced hypoxic effects leading to collagen and fibroblast degeneration<sup>26</sup> and matrix metalloproteinase activation<sup>27</sup> have been postulated as possible modes of action, to name only a few propositions. Nevertheless, a 2009 meta-analysis concluded that the overall effects of pressure garment therapy on global scar scores were of equivocal clinical significance, the associated morbidity and cost were not trivial, and no beneficial effects were proven.<sup>28</sup> As with other approaches, pressure dressings are still accepted as standard practice in many centers, especially for managing burn-induced scars,<sup>25</sup> but additional studies are clearly essential.

### Onion extracts

There are *in vitro* studies suggesting that onion extracts may accelerate wound healing by exerting a number of effects on mast cells and fibroblasts in the inflammatory cascade, and by decreasing inflammation.<sup>29-34</sup> In a recent study, both crude onion extracts and quercetin, which is one of its flavonoid ingredients, were investigated for their effects on the proliferation of fibroblasts, expression of type I collagen, and matrix metalloproteinase-1. Interestingly, the proliferation rates of fibroblasts were found to be decreased in a dose-dependent manner for both the crude onion extract and quercetin and matrix metalloproteinase-1 expression was found to be upregulated.<sup>35</sup>

Despite the encouraging laboratory data, early clinical studies on postsurgical scars were disappointing.<sup>36,37</sup> More recently, a gel containing onion has been reported to exert beneficial effects, both in combination with intralesional corticosteroids<sup>38</sup> and alone<sup>39</sup> in the overall appearance of hypertrophic scars. Nevertheless, these recent studies are small-

scale and not double-blind and randomized, and there is therefore no solid evidence base in support of the use of onion extract-based products.

### Vitamin E-based remedies

Vitamin E is commonly used in commercially available antiscarring products. Anecdotal reports had claimed that its topical application might accelerate wound healing and enhance the cosmetic outcome of postsurgical scars via its antioxidant properties, but early clinical studies yielded disappointing results.<sup>40</sup> Not only did it not seem to improve the appearance of scars when applied after surgery, but there was marked incidence of localized adverse effects contributing to worse outcome.<sup>40</sup> Similar findings were reported when a gel containing vitamin E was used either alone or in combination with a topical corticosteroid for scars after reconstructive surgery.<sup>41</sup> More recently, small clinical studies reported positive data when vitamin E was used alone or in combination presurgery, postsurgery,<sup>42,43</sup> and in systemic sclerosis-related digital ulcers.<sup>44</sup>

Overall, there is very little evidence base in support of the topical use of vitamin E as a strategy to minimize cutaneous scarring. More research is essential before any recommendations for adopting vitamin E as a means for minimizing scarring are implemented in clinical practice.

### Corticosteroids

Corticosteroids are thought to reduce scar formation by a number of mechanisms: by suppressing inflammation; by inhibiting fibroblast growth proliferation collagen synthesis; by causing vasoconstriction, thereby limiting wound oxygenation and nutrition; by effects on transforming growth factor-beta 1 (TGF $\beta$ <sub>1</sub>) and TGF $\beta$ <sub>2</sub> and collagen in keratinocytes; and by promoting collagen degeneration.<sup>45-49</sup> Intralesional triamcinolone is most commonly used for the treatment of scars, and a number of studies have reported variable efficacy (50-100%) with recurrence varying from 9% to 50%.<sup>50-54</sup> The reported beneficial outcome of intralesional steroid therapy is often associated with adverse effects, such as dermal atrophy and hypopigmentation; these are fewer when steroids are used in combination with 5-fluorouracil (5-FU) and pulsed-dye laser (PDL), mainly because of the lower steroid doses that are required.<sup>51,55-57</sup> Despite the relative lack of well designed studies, the consensus places intralesional triamcinolone as a recommended first-line approach for hypertrophic and keloid scars.<sup>58</sup> Topical corticosteroids, on the other hand, have failed to reduce scar tissue formation and are not advocated as a preferred modality.<sup>59,60</sup>

### 5-fluorouracil

Case series suggest that this pyrimidine analogue antimetabolite may be of benefit in hypertrophic scars and keloids when used intralesionally.<sup>61,62</sup> It has been shown to inhibit human fibroblast growth, and this is a possible mechanism of action.<sup>63</sup> Intralesional 5-FU is generally well tolerated and is associated with a humble constellation of acceptable topical side effects comprising erythema and pigmentation.<sup>64</sup> Side effects are fewer, and the achieved efficacy appears to improve when 5-FU is combined with corticosteroids and PDL for treating hypertrophic scars and keloids.<sup>65</sup>

### Bleomycin

In addition to its widespread uses as an antitumour agent, bleomycin has been reported to improve the appearance of hypertrophic and keloid scars when administered intradermally.<sup>66-68</sup> Direct or indirect, TGF $\beta$ -mediated, inhibitory effects on collagen<sup>69,70</sup> have been proposed as potential mechanisms of action. Occasionally reported complications include atrophy and hypopigmentation,<sup>71</sup> and intralesional bleomycin seems to be a reasonably attractive scar reduction therapeutic option. Nevertheless, additional and larger research studies are essential to assess the benefits of bleomycin.

## SURGERY, LASERS, AND RADIATION

### Key points

- **The surgical revision of hypertrophic scars is rarely performed because of high recurrence rates, but cryotherapy has been widely used with success**
- **Lasers are widely used in practice, and pulsed-dye laser therapy has shown efficacy, has a low-risk adverse effect profile, and is becoming increasingly popular as a pre- and postsurgery scar reduction modality**
- **Radiotherapy tends to be reserved as a late resort for resistant scars and is used sparingly because of concerns over carcinogenic potential**

### Surgery

Scar revision after cutaneous surgery may be essential if hypertrophic or keloid scars are a procedural aftermath. The high recurrence rates associated with simple total surgical excision of keloids are disappointing.<sup>72</sup> Subtotal excisions, where a rim of keloid is left behind, has been advocated to result in a better outcome because of low wound tension and decreased collagen synthesis.<sup>73</sup> Small hypertrophic scars may successfully be managed by the scar reorientating and tension-releasing Z- and W-plasties,

but the use of nonsurgical adjuvant therapy is recommended.<sup>74</sup>

It should be highlighted that the evidence base for the surgical strategies outlined above is overall inadequate and caution is advised before adopting them in clinical practice.

### Cryosurgery

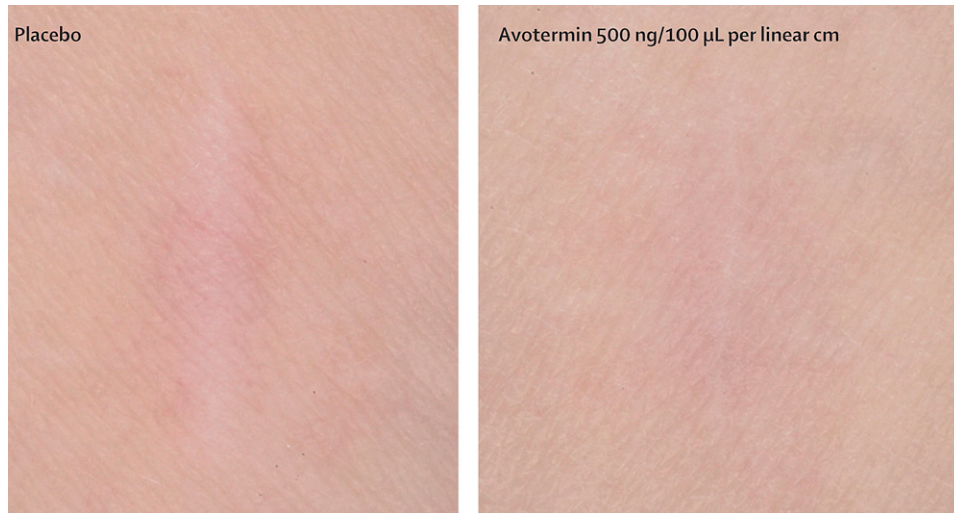
Cryotherapy has long been used in dermatology for hypertrophic scars and keloids. The mechanism by which the cold agent (most commonly liquid nitrogen) induces scar tissue destruction is by the direct cell freezing effects and by inferring vascular stasis after thawing.<sup>75</sup> A recent technological advancement has been the development of an intralesional cryoneedle, which is reported to be superior to the conventional open-spray or cryoprobe approach and is associated with fewer adverse reactions.<sup>76</sup> Volume reductions of 50%, 60%, and 67% of hypertrophic scars and keloids have been reported after a single intralesional cryogenic session.<sup>76-78</sup> Intralesional local anaesthesia and oral analgesics have been used successfully for procedure-associated pain control.<sup>78</sup> The safety profile of cryosurgery and the relative effectiveness in hypertrophic scars and keloids render it an attractive first-line scar reduction strategy despite a lack of level I evidence. It is often used in combination with intralesional corticosteroid therapy.

### Laser therapy

Laser light can be used for preventing and revising hypertrophic or keloid scars, and several lasers and light sources have been used to improve the appearance of such scars.

The first lasers used were ablative (ie, causing tissue vaporization), nonselective lasers and comprised the carbon dioxide (CO<sub>2</sub>) or an erbium:yttrium-aluminium-garnet (Er:YAG) laser. The former type effects wound contraction and collagen remodelling by causing thermal necrosis,<sup>79</sup> and it has also been reported to activate the release of basic fibroblast growth factor (bFGF) and inhibit TGF $\beta$ <sub>1</sub>.<sup>80</sup> The latter laser type has also been associated with altered levels of TGF $\beta$  orchestrated by a heat shock response.<sup>81</sup> Neither efficiently modified the wound healing response, and both were associated with significant adverse reactions, including major burns,<sup>82</sup> and therefore alternative approaches were sought.

These comprised the PDL (585 and 595 nm) and laser-assisted skin healing laser (810 nm). A 2010 review reported that both of these provide excellent clinical results while being well tolerated.<sup>82</sup> The 585-nm pulsed laser has long been praised as



**Fig 1.** Therapeutic application of avotermin to incisional wounds improves scarring compared to control treatment (placebo or standard wound care). (Adapted from *The Lancet* (Ferguson et al<sup>99</sup>) with permission from Elsevier and from the author.)

an excellent and safe choice for hypertrophic and keloid scar treatment, with effects on scar erythema, scar volume, and texture.<sup>83,84</sup> A 2011 systematic review evaluated seven laser types and found most evidence for the PDL 585-nm followed by PDL 595-nm. It was thought that the 595-nm wavelength was more promising with a moderate efficacy (34-66% improvement) as compared to PDL 585 nm, which was found to have low efficacy (0-33% improvement).<sup>85</sup> On the side of caution, there are some reports suggesting rapid scar recurrence with pulsed laser treatment of keloid scars,<sup>86</sup> and combination treatment with intralesional corticosteroids and/or 5-FU therapy has been advocated as possibly superior to either approach alone.<sup>56</sup>

Fractional laser therapy and intense pulsed light therapy are relatively recent developments that are also used in clinical practice for improving the appearance of surgical scars. Nonablative fractional lasers are more favorable than ablative ones because of a reportedly better safety profile and efficacy. They are supposed to work by causing localized thermal injury and epidermal necrosis over the so-called microscopic thermal zones that are non-contiguous—that is, they are separated by zones of intact tissue. The intact tissue surrounding each thermal zone serves as reservoir of normal dermal and epidermal cells, which migrate to the damaged area to effect efficient and prompt healing.<sup>87,88</sup> Nonetheless, there is a limited evidence base to support the use of fractional laser therapy<sup>89</sup> and almost no evidence base in support of intense pulsed light therapy.<sup>85</sup>

### Radiotherapy

Radiation therapy is a modality that is usually reserved for keloid and hypertrophic scars that are resistant to other treatments, and it is not widely used, at least in part because of concerns about carcinogenic potential.<sup>53,90</sup> The underlying mechanism of action involves induction of apoptosis in fibroblasts and subsequent restoration of the balance between formation and breakdown of scar collagen, while altered gene expression and connective tissue stem cell damage have also been reported.<sup>91-94</sup> High success rates have been reported for radiation therapy in keloid scars; recurrence is lower when radiotherapy is used as adjuvant to surgery and response varies widely according to the site of the lesion.<sup>54,95-98</sup> Side effects are generally minimal and include hyperpigmentation, pruritus, and erythema.<sup>52</sup> Interestingly, radiation relieves hypertrophic scar and keloid-associated symptoms, notably pruritus and local discomfort.<sup>26</sup>

## INNOVATIVE MEDICAL APPROACHES

### Key points

- **Avotermin, human recombinant interleukin-10, and to a lesser extent mannose-6-phosphate are novel agents showing promising results in randomized controlled trials and are likely to change practice when they become commercially available**
- **Insulin, mitomycin C, topical tamoxifen, systemic methotrexate, topical imiquimod, retinoic acid, botulinum toxin A, calcineurin inhibitors, and calcium channel blockers**

**Table I.** Proposed mechanisms of action and comments on evidence base for commonly used and innovative scar-reducing modalities

Modality	Mechanism of action	Comments	Level of evidence
Silicone dressings	Temperature, oxygen tension, and hydration regulation <sup>6</sup>	Intermittent reports; discouraging Cochrane review <sup>21</sup> ; still widely used (good safety profile)	III
Pressure dressings	Pressure-induced hypoxic effects leading to collagen and fibroblast degeneration <sup>26</sup> ; MMP-9 activation <sup>27</sup>	Equivocal clinical significance in 2009 meta-analysis <sup>28</sup> ; still commonly used (good safety profile)	—
Onion extracts	Affects fibroblasts and mast cells in the inflammatory cascade and by decreasing inflammation <sup>29-34</sup> ; decreased proliferation rates of fibroblasts <sup>35</sup>	Small, nonrandomized, not well controlled clinical studies; still commonly used OTC product	IIB
Vitamin E-based remedies	Antioxidant properties <sup>40</sup>	Some negative data; little support (small clinical studies); not very commonly used	IIB/III
Corticosteroids	Inhibit fibroblast growth proliferation collagen synthesis; cause vasoconstriction, thereby limiting wound oxygenation and nutrition; have effects on TGF $\beta_1$ , TGF $\beta_2$ and collagen in keratinocytes; promote collagen degeneration <sup>45-49</sup>	Numerous positive case studies (albeit lack of well controlled trials) for intralesional corticosteroids; topical agents not recommended; intralesional agents advocated by many as first-line; often used in combination with other modalities	III
5-Fluorouracil	Inhibit human fibroblast growth <sup>63</sup>	Case series; used by some in practice	III
Bleomycin	Direct or indirect TGF $\beta$ -mediated, inhibitory effects on collagen <sup>69,70</sup>	Support for intralesional application by case studies/preliminary clinical trial; used by some in practice but associated with adverse reactions	III
Lasers	Effect wound contraction and collagen remodelling by thermal necrosis <sup>79</sup> ; activates release of bFBG and inhibits TGF $\beta_1$ <sup>80</sup> ; altered levels of TGF $\beta$ by a heat shock response <sup>81</sup>	Some support for PDLs by systematic review (2011); several types are widely used in practice	IA (for PDL)
Surgery	Scar revision, reorientation, and tension release	Z- and W-plasty supported by case studies, but additional modalities recommended in combination; not used as first-line because of high recurrence rates; adjuvant treatment is recommended	III
Cryosurgery	Direct cell freezing effects and by inferring vascular stasis after thawing <sup>75</sup>	Support from review of numerous case studies; lack of level I evidence but widely used; often in combination with intralesional corticosteroids	III
Radiation	Induction of apoptosis in fibroblasts; restoration of balance between formation and breakdown of scar collagen; altered gene expression and connective tissue stem cell damage <sup>87-90</sup>	Reported success in reports and case series; not widely used because of questionable safety profile	III
Avotermin	Therapeutic application of recombinant TGF $\beta_3$ (receptor antagonist reducing scarring)	Intradermal formulation in development; shown to provide an accelerated and permanent improvement in scarring with transient and clinically insignificant adverse effects in early studies (three double-blind, placebo-controlled, phase I/II studies) <sup>95</sup>	IB

Continued

**Table I.** Cont'd

Human recombinant IL-10	Intradermal application of human recombinant IL-10, antiinflammatory cytokine that reduces scarring	A single-center, double-blind, standard care— and placebo-controlled, randomized phase II clinical trial reported a statistically significant reduction of scarring <sup>99</sup>	IB
Mannose-6-phosphate	Potent inhibitor of TGF $\beta_1$ and TGF $\beta_2$ signaling <sup>101</sup>	Positive phase I clinical trial results <sup>101</sup> but unmet primary endpoints thereafter; in development as topical formulation	IB; topical formulation not tested
Insulin	Inhibitor of myofibroblast <sup>105</sup>	Small pilot study with encouraging results <sup>104</sup> ; not widely used	IB (small-scale study)

*bFBG*, basic fibroblast growth factor; *IL-10*, interleukin-10; *MMP-9*, matrix metalloproteinase; *OTC*, over the counter; *PDL*, pulsed-dye laser; *TGF $\beta$* , transforming growth factor—beta.

**have been tested only sporadically and in small-scale studies (some randomized)**

- **More extensive well controlled trials are necessary to test agents that have shown some evidence of efficacy but have not yet passed the acid test**

The identified inadequacy in antiscarring therapeutics initiated the search for efficacious scar-reducing agents by using innovative approaches. Indeed, the wealth of data produced by molecular research on wound healing has led to the development of novel therapeutic strategies that aim to reduce human scarring efficiently.

**Novel and promising**

**Avotermin.** Avotermin is a therapeutic application of recombinant TGF $\beta_3$  that has been shown to reduce scar size. In clinical trials assessing its efficacy at different body sites, skin colors, ages, and sexes, scar appearance after treatment with intradermal injection of avotermin has been judged by a panel of laypeople and a panel of clinical investigators over the time period of 2 weeks to 1 year. A recent paper summarizing three double blind, placebo-controlled, phase I/II studies (level IB) concludes that avotermin bears the potential to provide an accelerated and permanent improvement in scarring (Fig 1) with transient and clinically insignificant adverse effects.<sup>99</sup> Avotermin is aimed at both prophylaxis against and treatment of surgical scars. The ongoing European double blind placebo-controlled clinical trial is investigating the efficacy of intradermal avotermin in excisional scar revision surgery, a procedure commonly performed by cosmetic dermatologists and plastic surgeons for disfiguring, aesthetically unpleasant, or complicated scars.<sup>101</sup> The first data are expected to be reported in the last quarter of 2011.<sup>100</sup> Other injectable agents, such

as antisense TGF oligonucleotides have been tested postsurgically with some success in humans.<sup>101,102</sup> Avotermin is the only molecule targeting TGF $\beta_3$  to date that has been tested and progressed adequately.

**Human recombinant interleukin-10.** To date, a single-center, double blind, standard care— and placebo-controlled randomized phase II clinical trial has been conducted (level IB) to examine the efficacy of a therapeutic formulation of intradermal injections of human recombinant interleukin-10 on wound healing. This trial examined the appearance of healed scars after the injection of eight different doses of human recombinant interleukin-10 into the margins of surgical incisional wounds. Patients who received treatment had a statistically significant reduction of scarring.<sup>103</sup> An ongoing trial is aiming at primarily establishing the effects of four different intradermal doses of the same agent on incisional and excisional scars in subjects of African ancestry as compared to placebo.<sup>104</sup>

**Mannose-6-phosphate.** The recently developed formulation of mannose-6-phosphate is a potent inhibitor of TGF $\beta_1$  and TGF $\beta_2$  signalling and therefore a potential therapeutic agent for scar reduction. Following positive phase I clinical trial results<sup>105</sup> (level IB), the manufacturer investigated the application of mannose-6-phosphate in a phase II trial.<sup>106</sup> In this trial, the agent was applied via two different routes of administration (topically and intradermally) to the donor site of split thickness skin grafts and the resultant scar profile was examined. Although this exploratory trial did not meet its primary end points with statistical significance, a number of prespecified secondary endpoints were met, and the manufacturer believes that the agent can potentially be used for improved cosmesis following certain minor dermatologic interventions, such as dermabrasion and laser peeling.<sup>107</sup>



### Novel but inadequately researched

**Insulin.** A pilot study run by National Health Service Innovation investigated the role of insulin in scar reduction. Fifteen patients undergoing bilateral breast reduction surgery received insulin injections in the wound margins of one breast and saline placebo in the contralateral breast. Although there is otherwise limited research evidence suggesting insulin has an antiscarring effect, this small but randomized controlled study reported that insulin administration improved scar profile.<sup>108</sup> Insulin has been recognized as an inhibitor of the fibrosis-associated fibroblast phenotype, the myofibroblast, and this has been advocated as a potential mechanism of insulin's action as an antiscarring agent.<sup>109</sup>

**Other agents.** Mitomycin C, topical tamoxifen, systemic methotrexate, topical imiquimod, retinoic acid, botulinum toxin A, calcineurin inhibitors, and calcium channel blockers have been sporadically investigated in small-scale studies.<sup>110</sup> The evidence base underpinning the use of such agents is inadequate. Larger, well designed, double blinded, randomized controlled clinical trials are essential before any credible suggestions for therapeutic use can be made.

### CONCLUSION

It should be noted that lack of adequate evidence does not necessarily imply evidence of inadequacy. The present review is not an exhaustive account of evidence-based scar reduction strategies. The selectively discussed conventional modalities are widely available and commonly used, and there is some evidence in support of their use. Each patient is nonetheless different, and the practicing dermatologist must formulate a treatment strategy having considered guidelines on a par with personal clinical experience and individual patient needs.

The innovative promising agents that are currently being developed are a testament to the invaluable contribution of translational research in medicine—translating molecular advances into practical therapeutic modalities.

So the question “Will there be a scar?” will, perhaps one day in the not too distant future, be answered with “No, not one that you can see!”

We thank Professor David Burden, Dr Craig Dick, and Professor Barry Gusterson for kindly reviewing the manuscript.

### REFERENCES

1. Juckett G, Hartman-Adams H. Management of keloids and hypertrophic scars. *Am Fam Physician* 2009;80:253-60.
2. Leventhal D, Furr M, Reiter D. Treatment of keloids and hypertrophic scars. *Arch Facial Plast Surg* 2006;8:362-8.
3. Ogawa R. Keloid and hypertrophic scarring may result from a mechanoreceptor or mechanosensitive nociceptor disorder. *Med Hypotheses* 2008;71:493-500.
4. Aarabi S, Bhatt KA, Shi Y, Paterno J, Chang EI, Loh SA, et al. Mechanical load initiates hypertrophic scar formation through decreased cellular apoptosis. *FASEB J* 2007;21:3250-61.
5. Kelly AP. Keloids and hypertrophic scars. In: Parish LC, Lask GP, editors. *Aesthetic Dermatology*. New York, NY: McGraw-Hill; 1991. pp. 8-69.
6. Berman B, Perez OA, Konda S, Kohut BE, Viera MH, Delgado S, et al. A review of the biologic effects, clinical efficacy, and safety of silicone elastomer sheeting for hypertrophic and keloid scar treatment and management. *Dermatol Surg* 2007;33:1291-303.
7. Atkinson JA, McKenna KT, Barnett AG, McGrath DJ, Rudd M. A randomized, controlled trial to determine the efficacy of paper tape in preventing hypertrophic scar formation in surgical incisions that traverse Langer's skin tension lines. *Plast Reconstr Surg* 2005;116:1648-58.
8. Reiffel RS. Prevention of hypertrophic scars by long-term paper tape application. *Plast Reconstr Surg* 1995;96:1715-8.
9. Wang J, Hori K, Ding J, Huang Y, Kwan P, Ladak A, et al. Toll-like receptors expressed by dermal fibroblasts contribute to hypertrophic scarring. *J Cell Physiol* 2011;226:1265-73.
10. Coulthard P, Esposito M, Worthington HV, van der Elst M, van Waes OJ, Darcey J. Tissue adhesives for closure of surgical incisions. *Cochrane Database Syst Rev* 2010;5:CD004287.
11. Moy RL, Waldman B, Hein DW. A review of sutures and suturing techniques. *J Dermatol Surg Oncol* 1992;18:785-95.
12. Hohenleutner U, Egner N, Hohenleutner S, Landthaler M. Intradermal buried vertical mattress suture as sole skin closure: evaluation of 149 cases. *Acta Derm Venereol* 2000;80:344-7.
13. Zuber TJ. The mattress sutures: vertical, horizontal, and corner stitch. *Am Fam Physician* 2002;66:2231-6.
14. Luck RP, Flood R, Eyal D, Saludades J, Hayes C, Gaughan J. Cosmetic outcomes of absorbable versus nonabsorbable sutures in pediatric facial lacerations. *Pediatr Emerg Care* 2008;24:137-42.
15. Karounis H, Gouin S, Eisman H, Chalut D, Pelletier H, Williams B. A randomized, controlled trial comparing long-term cosmetic outcomes of traumatic pediatric lacerations repaired with absorbable plain gut versus nonabsorbable nylon sutures. *Acad Emerg Med* 2004;11:730-5.
16. Parell GJ, Becker GD. Comparison of absorbable with nonabsorbable sutures in closure of facial skin wounds. *Arch Facial Plast Surg* 2003;5:488-90.
17. Durkaya S, Kaptanoglu M, Nadir A, Yilmaz S, Cinar Z, Dogan K. Do absorbable sutures exacerbate presternal scarring? *Tex Heart Inst J* 2005;32:544-8.
18. Al-Abdullah T, Plint AC, Fergusson D. Absorbable versus nonabsorbable sutures in the management of traumatic lacerations and surgical wounds: a meta-analysis. *Pediatr Emerg Care* 2007;23:339-44.
19. Niessen FB, Spauwen PH, Kon M. The role of suture material in hypertrophic scar formation: monocryl vs. vicryl-rapide. *Ann Plast Surg* 1997;39:254-60.
20. Shih R, Waltzman J, Evans GR. Review of over-the-counter topical scar treatment products. *Plast Reconstr Surg* 2007;119:1091-5.
21. O'Brien L, Pandit A. Silicon gel sheeting for preventing and treating hypertrophic and keloid scars. *Cochrane Database Syst Rev* 2006;1:CD003826.
22. Morganroth P, Wilmot AC, Miller C. Over-the-counter scar products for postsurgical patients: disparities between online

- advertised benefits and evidence regarding efficacy. *J Am Acad Dermatol* 2009;61:e31-47.
23. Mustoe TA, Cooter RD, Gold MH, Hobbs FD, Ramelet AA, Shakespeare PG, et al. International clinical recommendations on scar management. *Plast Reconstr Surg* 2002;110:560-71.
  24. McGrath M. Topical scar modification: help or hype? *Aesthet Surg J* 2005;25:304-6.
  25. Puzey G. The use of pressure garments on hypertrophic scars. *J Tissue Viability* 2002;12:11-5.
  26. Kelly AP. Medical and surgical therapies for keloids. *Dermatol Ther* 2004;17:212-8.
  27. Renò F, Grazianetti P, Stella M, Magliacani G, Pezzuto C, Cannas M. Release and activation of matrix metalloproteinase-9 during in vitro mechanical compression in hypertrophic scars. *Arch Dermatol* 2002;138:475-8.
  28. Anzarut A, Olson J, Singh P, Rowe BH, Tredget EE. The effectiveness of pressure garment therapy for the prevention of abnormal scarring after burn injury: a meta-analysis. *J Plast Reconstr Aesthet Surg* 2009;62:77-84.
  29. Dorsch W, Schneider E, Bayer T, Breu W, Wagner H. Anti-inflammatory effects of onions: inhibition of chemotaxis of human polymorphonuclear leukocytes by thiosulfates and cepaenes. *Int Arch Allergy Appl Immunol* 1990;92:39-42.
  30. Johri RK, Zutshi U, Kameshwaran L, Atal CK. Effect of quercetin and *Albizia saponins* on rat mast cell. *Indian J Physiol Pharmacol* 1985;29:43-6.
  31. Pawlikowska-Pawlega B, Gawron A. Effect of quercetin on the growth of mouse fibroblast cells in vitro. *Pol J Pharmacol* 1995;47:531-5.
  32. Ross ZM, O'Gara EA, Hill DJ, Sleightholme HV, Maslin DJ. Antimicrobial properties of garlic oil against human enteric bacteria: evaluation of methodologies and comparisons with garlic oil sulfides and garlic powder. *Appl Environ Microbiol* 2001;67:475-80.
  33. Augusti KT. Therapeutic values of onion (*Allium cepa* L.) and garlic (*Allium sativum* L.). *Indian J Exp Biol* 1996;34:634-40.
  34. Elnima El, Ahmed SA, Mekkawi AG, Mossa JS. The antimicrobial activity of garlic and onion extracts. *Pharmazie* 1983;38:747-8.
  35. Cho JW, Cho SY, Lee SR, Lee KS. Onion extract and quercetin induce matrix metalloproteinase-1 in vitro and in vivo. *Int J Mol Med* 2010;25:347-52.
  36. Jackson BA, Shelton AJ. Pilot study evaluating topical onion extract as treatment for postsurgical scars. *Dermatol Surg* 1999;25:267-9.
  37. Chung VQ, Kelley L, Marra D, Jiang SB. Onion extract gel versus petrolatum emollient on new surgical scars: prospective double-blinded study. *Dermatol Surg* 2006;32:193-7.
  38. Koc E, Arca E, Surucu B, Kurumlu Z. An open, randomized, controlled, comparative study of the combined effect of intralesional triamcinolone acetonide and onion extract gel and intralesional triamcinolone acetonide alone in the treatment of hypertrophic scars and keloids. *Dermatol Surg* 2008;34:1507-14.
  39. Campanati A, Savelli A, Sandroni L, Marconi B, Giuliano A, Giuliadori K, et al. Effect of allium cepa-allantoin-pentaglycan gel on skin hypertrophic scars: clinical and video-capillaroscopic results of an open-label, controlled, non-randomized clinical trial. *Dermatol Surg* 2010;36:1439-44.
  40. Baumann LS, Spencer J. The effects of topical vitamin E on the cosmetic appearance of scars. *Dermatol Surg* 1999;25:311-5.
  41. Jenkins M, Alexander JW, MacMillan BG, Waymack JP, Kopcha R. Failure of topical steroids and vitamin E to reduce postoperative scar formation following reconstructive surgery. *J Burn Care Rehabil* 1986;7:309-12.
  42. Perez OA, Viera MH, Patel JK, Konda S, Amini S, Huo R, et al. A comparative study evaluating the tolerability and efficacy of two topical therapies for the treatment of keloids and hypertrophic scars. *J Drugs Dermatol* 2010;9:514-8.
  43. Zampieri N, Zuin V, Burro R, Ottolenghi A, Camoglio FS. A prospective study in children: pre- and post-surgery use of vitamin E in surgical incisions. *J Plast Reconstr Aesthet Surg* 2010;63:1474-8.
  44. Fiori G, Galluccio F, Braschi F, Amanzi L, Miniati I, Conforti ML, et al. Vitamin E gel reduces time of healing of digital ulcers in systemic sclerosis. *Clin Exp Rheumatol* 2009;27(3 suppl. 54):51-4.
  45. Fässler R, Sasaki T, Timpl R, Chu ML, Werner S. Differential regulation of fibulin, tenascin-C, and nidogen expression during wound healing of normal and glucocorticoid-treated mice. *Exp Cell Res* 1996;222:111-6.
  46. Pérez P, Page A, Bravo A, Del Río M, Giménez-Conti I, Budunova I, et al. Altered skin development and impaired proliferative and inflammatory responses in transgenic mice overexpressing the glucocorticoid receptor. *FASEB J* 2001;15:2030-2.
  47. Stojadinovic O, Lee B, Vouthounis C, Vukelic S, Pastar I, Blumenberg M, et al. Novel genomic effects of glucocorticoids in epidermal keratinocytes: inhibition of apoptosis, interferon-gamma pathway, and wound healing along with promotion of terminal differentiation. *J Biol Chem* 2007;282:4021-34.
  48. Wu WS, Wang FS, Yang KD, Huang CC, Kuo YR. Dexamethasone induction of keloid regression through effective suppression of VEGF expression and keloid fibroblast proliferation. *J Invest Dermatol* 2006;126:1264-71.
  49. Alster TS, West TB. Treatment of scars: a review. *Ann Plast Surg* 1997;39:418-32.
  50. Tang YW. Intra and postoperative steroid injections for keloids and hypertrophic scars. *Br J Plast Surg* 1992;45:371-3.
  51. Manuskhatti W, Fitzpatrick RE. Treatment response of keloidal and hypertrophic sternotomy scars: comparison among intralesional corticosteroid, 5-fluorouracil, and 585-nm flashlamp-pumped pulsed-dye laser treatments. *Arch Dermatol* 2002;138:1149-55.
  52. Darzi MA, Chowdri NA, Kaul SK, Khan M. Evaluation of various methods of treating keloids and hypertrophic scars: a 10-year follow-up study. *Br J Plast Surg* 1992;45:374-9.
  53. Niessen FB, Spauwen PH, Schalkwijk J, Kon M. On the nature of hypertrophic scars and keloids: a review. *Plast Reconstr Surg* 1999;104:1435-58.
  54. Shaffer JJ, Taylor SC, Cook-Bolden F. Keloidal scars: a review with a critical look at therapeutic options. *J Am Acad Dermatol* 2002;46(2 suppl understanding):S63-97.
  55. Maguire HC Jr. Treatment of keloids with triamcinolone acetonide injected intralesionally. *JAMA* 1956;192:325-6.
  56. Asilian A, Darougheh A, Shariati F. New combination of triamcinolone, 5-fluorouracil, and pulsed-dye laser for treatment of keloid and hypertrophic scars. *Dermatol Surg* 2006;32:907-15.
  57. Alster TS. Laser scar revision: comparison study of 585-nm pulsed dye laser with and without intralesional corticosteroids. *Dermatol Surg* 2003;29:25-9.
  58. Chowdri NA, Masarat M, Mattoo A, Darzi MA. Keloids and hypertrophic scars: results with intraoperative and serial postoperative corticosteroid injection therapy. *Aust N Z J Surg* 1999;69:655-9.

59. Widgerow AD, Chait LA, Stals R, et al. New innovations in scar management. *Aesthetic Plast Surg* 2000;24:227-34.
60. Yii NW, Frame JD. Evaluation of cythaskin and topical steroid in the treatment of hypertrophic scars and keloids. *Eur J Plast Surg* 1996;19:162-5.
61. Nanda S, Reddy BS. Intralesional 5-fluorouracil as a treatment modality of keloids. *Dermatol Surg* 2004;30:54-7.
62. Kontochristopoulos G, Stefanaki C, Panagiotopoulos A, Stefanaki K, Argyrakos T, Petridis A, et al. Intralesional 5-fluorouracil in the treatment of keloids: an open clinical and histopathologic study. *J Am Acad Dermatol* 2005; 52(3 pt 1):474-9.
63. de Waard JW, de Man BM, Wobbes T, van der Linden CJ, Hendriks T. Inhibition of fibroblast collagen synthesis and proliferation by levamisole and 5-fluorouracil. *Eur J Cancer* 1998;34:162-7.
64. Apikian M, Goodman G. Intralesional 5-fluorouracil in the treatment of keloid scars. *Australas J Dermatol* 2004;45: 140-3.
65. Fitzpatrick RE. Treatment of inflamed hypertrophic scars using intralesional 5-FU. *Dermatol Surg* 1999;25:224-32.
66. Saray Y, Güleç AT. Treatment of keloids and hypertrophic scars with dermojet injections of bleomycin: a preliminary study. *Int J Dermatol* 2005;44:777-84.
67. Naeini FF, Najafian J, Ahmadpour K. Bleomycin tattooing as a promising therapeutic modality in large keloids and hypertrophic scars. *Dermatol Surg* 2006;32:1023-30.
68. España A, Solano T, Quintanilla E. Bleomycin in the treatment of keloids and hypertrophic scars by multiple needle punctures. *Dermatol Surg* 2001;27:23-7.
69. Hendricks T, Martens MF, Huyben CM, Wobbes T. Inhibition of basal and TGF beta-induced fibroblast collagen synthesis by antineoplastic agents. Implications for wound healing. *Br J Cancer* 1993;67:545-50.
70. Yeowell HN, Marshall MK, Walker LC, Ha V, Pinnell SR. Regulation of lysyl oxidase mRNA in dermal fibroblasts from normal donors and patients with inherited connective tissue disorders. *Arch Biochem Biophys* 1994;308:299-305.
71. Bodokh I, Brun P. Treatment of keloid with intralesional bleomycin [in French]. *Ann Dermatol Venereol* 1996;123: 791-4.
72. Berman B, Bielew HC. Adjunct therapies to surgical management of keloids. *Dermatol Surg* 1996;22:126-30.
73. Engrav LH, Gottlieb JR, Millard SP, Walkinshaw MD, Heimbach DM, Marvin JA. A comparison of intramarginal and extramarginal excision of hypertrophic burn scars. *Plast Reconstr Surg* 1988;81:40-5.
74. English RS, Shenefelt PD. Keloids and hypertrophic scars. *Dermatol Surg* 1999;25:631-8.
75. Zouboulis CC. Cryosurgery in dermatology. *Eur J Dermatol* 1998;8:466-74.
76. Har-Shai Y, Amar M, Sabo E. Intralesional cryotherapy for enhancing the involution of hypertrophic scars and keloids. *Plast Reconstr Surg* 2003;111:1841-52.
77. Har-Shai Y, Sabo E, Rohde E, Hayms M, Assaf C, Zouboulis CC. Intralesional cryosurgery markedly enhances the involution of recalcitrant auricular keloids: a new clinical approach supported by experimental studies. *Wound Repair Regen* 2006;14:18-27.
78. Har-Shai Y, Brown W, Labbé D, Domp Martin A, Goldine I, Gil T, et al. Intralesional cryosurgery for the treatment of hypertrophic scars and keloids following aesthetic surgery. *Int J Lower Extrem Wounds* 2008;7:169-75.
79. Lee KK, Mehrany K, Swanson NA. Surgical revision. *Dermatol Clin* 2005;23:141-50.
80. Nowak KC, McCormack M, Koch RJ. The effect of superpulsed carbon dioxide laser energy on keloid and normal dermal fibroblast secretion of growth factors: a serum-free study. *Plast Reconstr Surg* 2000;105:2039-48.
81. Capon A, Mordon S. Can thermal lasers promote skin wound healing? *Am J Clin Dermatol* 2003;4:1-12.
82. Leclère FM, Mordon SR. Twenty-five years of active laser prevention of scars: what have we learned? *J Cosmet Laser Ther* 2010;12:227-34.
83. Alster TS. Improvement of erythematous and hypertrophic scars by the 585-nm flashlamp-pumped pulsed dye laser. *Ann Plast Surg* 1994;32:186-90.
84. Alster TS, Williams CM. Treatment of keloid sternotomy scars with 585 nm flashlamp-pumped pulsed-dye laser. *Lancet* 1995;345:1198-200.
85. Vrijman C, van Drooge AM, Limpens CE, Bos JD, van der Veen JP, Spuls PI, et al. Laser and intense pulsed light therapy for the treatment of hypertrophic scars: a systematic review. *Br J Dermatol* 2011 Jun 28. [Epub ahead of print].
86. Shih PY, Chen HH, Chen CH, Hong HS, Yang CH. Rapid recurrence of keloid after pulse dye laser treatment. *Dermatol Surg* 2008;34:1124-7.
87. Alster TS. Cutaneous resurfacing with CO<sub>2</sub> and erbium: YAG lasers: preoperative, intraoperative, and postoperative considerations. *Plast Reconstr Surg* 1999;103:619-34.
88. Manstein D, Herron GS, Sink RK. Non-ablative fractional laser: a new concept for cutaneous remodeling using microscopic patterns of thermal injury. *Lasers Surg Med* 2004;34:426-38.
89. Tierney E, Mahmoud BH, Srivastava D, Ozog D, Kouba DJ. Treatment of surgical scars with nonablative fractional laser versus pulsed dye laser: a randomized controlled trial. *Dermatol Surg* 2009;35:1172-80.
90. Botwood N, Lewanski C, Lowdell C. The risks of treating keloids with radiotherapy. *Br J Radiol* 1999;72:1222-4.
91. Rockwell WB, Cohen IK, Ehrlich HP. Keloids and hypertrophic scars: a comprehensive review. *Plast Reconstr Surg* 1989;84: 827-37.
92. Luo S, Benathan M, Raffoul W, Panizzon RG, Egloff DV. Abnormal balance between proliferation and apoptotic cell death in fibroblasts derived from keloid lesions. *Plast Reconstr Surg* 2001;107:87-96.
93. Lee KS, Jung JB, Ro YJ, Ryoo YW, Kim OB, Song JY. Effects of x-irradiation on survival and extracellular matrix gene expression of cultured keloid fibroblasts. *J Dermatol Sci* 1994;8: 33-7.
94. Borok TL, Bray M, Sinclair I, Plafker J, LaBirth L, Rollins C. Role of ionizing irradiation for 393 keloids. *Int J Radiat Oncol Biol Phys* 1988;15:865-70.
95. Wagner W, Alfrink M, Micke O, Schäfer U, Schüller P, Willich N. Results of prophylactic irradiation in patients with resected keloids—a retrospective analysis. *Acta Oncol* 2000;39:217-20.
96. Klumpar DI, Murray JC, Anscher M. Keloids treated with excision followed by radiation therapy. *J Am Acad Dermatol* 1994;31:225-31.
97. Ragoowansi R, Cornes PG, Moss AL, Gleeves JP. Treatment of keloids by surgical excision and immediate postoperative single-fraction radiotherapy. *Plast Reconstr Surg* 2003;111: 1853-9.
98. Viani GA, Stefano EJ, Afonso SL, De Fendi LI. Postoperative strontium-90 brachytherapy in the prevention of keloids: results and prognostic factors. *Int J Radiat Oncol Biol Phys* 2009;73:1510-6.
99. Ferguson MWJ, Duncan J, Bond J, Bush J, Durani P, So K, et al. Prophylactic administration of avotermine for improvement of

- skin scarring: three double-blind, placebo-controlled, phase I/II studies. *Lancet* 2009;373:1264-74.
100. US National Institutes of Health, ClinicalTrials.gov web site. A double blind, within patient, placebo controlled trial to assess the efficacy of Juvista (avotermin) in conjunction with scar revision surgery for the improvement of disfiguring scars. Available from: <http://www.clinicaltrials.gov/ct2/show/NCT00742443>. Accessed February 16, 2010.
  101. Cordeiro MF, Mead A, Ali RR, Alexander RA, Murray S, Chen C, et al. Novel antisense oligonucleotides targeting TGF-beta inhibit in vivo scarring and improve surgical outcome. *Gene Ther* 2003;10:59-71.
  102. Choi BM, Kwak HJ, Jun CD, Park SD, Kim KY, Kim HR, et al. Control of scarring in adult wounds using antisense transforming growth factor beta1 oligodeoxynucleotides. *Immunol Cell Biol* 1996;74:144-50.
  103. US National Institutes of Health, ClinicalTrials.gov web site. A single-centre, placebo- and standard-care-controlled, double-blind, randomised trial to investigate the efficacy of eight doses of RN1003 in the reduction of scarring from the approximated wound margins of incisional wounds. Available from: <http://www.clinicaltrials.gov/ct2/show/NCT00984646>. Accessed February 18, 2010.
  104. US National Institutes of Health, ClinicalTrials.gov web site. An exploratory, single centre, randomized, placebo controlled, assessor blind clinical trial to assess the effects of intradermal administrations of Prevascar on scarring in human subjects of African continental ancestral origin. Available from: <http://www.clinicaltrials.gov/ct2/show/NCT01115868>. Accessed February 18, 2010.
  105. US National Institutes of Health, ClinicalTrials.gov web site. A trial to investigate the clinical safety, local toleration, and systemic pharmacokinetics of repeated, escalating concentrations of intradermal RN1004 to wounds of healthy subjects. Available from: <http://www.clinicaltrials.gov/ct2/show/NCT00984854>. Accessed February 18, 2010.
  106. US National Institutes of Health, ClinicalTrials.gov web site. A double blind, placebo controlled trial to investigate the efficacy and safety of two concentrations of Juvindex (mannose-6-phosphate) in accelerating the healing of split thickness skin graft donor sites using different dosing regimes. Available from: <http://www.clinicaltrials.gov/ct2/show/NCT00664352>. Accessed February 18, 2010.
  107. Renovo Web site. Available from: URL: <http://www.renovocom/en/products/juvidex>. Accessed October 15, 2011.
  108. Baker R, Sojitra N, Grobbelaar AO, Linge C. A randomised controlled trial of the efficacy of insulin as an antiscarring agent. *J Plast Reconstr Aesthetic Surg* 2007;60:S11.
  109. Baker R, Vigor C, Richardson J, Rolfe K, Grobbelaar A, Linge C. Potential mechanism of action of insulin as an anti-scarring agent. *J Plast Reconstr Aesthetic Surg* 2006;59:S3-4, [abstract].
  110. Viera MH, Amini S, Valins W, Berman B. Innovative therapies in the treatment of keloids and hypertrophic scars. *J Clin Aesthet Dermatol* 2010;3:20-6.